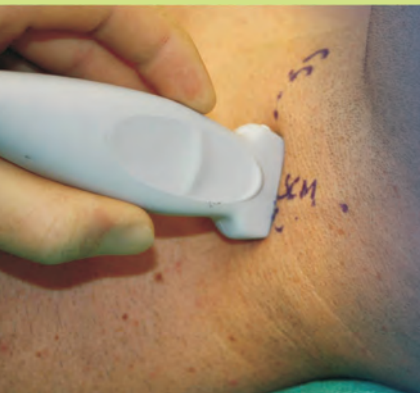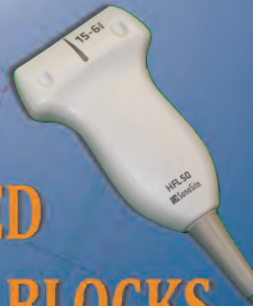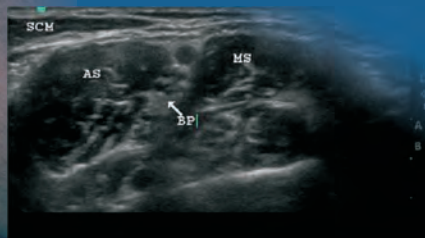


Landmarks for ULTRASOUND GUIDED PERIPHERAL NERVE BLOCKS

Upper and Lower Extremities



2010



Didier A. Sciard

Landmarks for Ultrasound Guided Peripheral Nerve Blocks

2010

Didier A. Sciard M.D.

*Associate Professor
Department of Anesthesiology
The University of Texas-Houston Medical School
Houston, Texas*

Contributing authors:

Peter Cheng, D.O.

*Department of Anesthesiology
KP Riverside Medical Center
Riverside, CA*

Eryck Eisenberg M.D.

*Department of Anesthesiology
Clinique « Pôle Santé République »
Clermont-Ferrand, France*

Copyright © 2010 Life-Tech

All rights reserved. Except for brief quotations for the purpose of criticism and review, no part of this publication may be reproduced, stored in a retrieval system, or transmitted in any form or by any means, electronic, mechanical, photocopying, recording or otherwise without the prior permission of the publisher.

Cover design by Life-Tech, Inc.

Text design by Marjolaine Sciard

Photographs by Mahammad Hussein, MD

Published and distributed by

Life-Tech, Inc.

PO Box 1849

Stafford, Texas 77947

Tel: 281-491-6600, 800-231-9841

Fax: 281-91-6646

Email: sales@life-tech.com

Website: www.life-tech.com

ISBN-13: 978-0-9752728-2-4

Life-Tech part number AB2

TABLE OF CONTENTS

INTRODUCTION	i
Anatomical Planes & Terminology	iii
Ultrasound Terminology.....	iv
UPPER EXTREMITY LANDMARKS	1
BRACHIAL PLEXUS BLOCKS.....	5
Ultrasound Guided Interscalene Block.....	15
Ultrasound Guided Supraclavicular Block.....	17
Ultrasound Guided Infraclavicular Block	20
Ultrasound Guided Axillary Block.....	23
Ultrasound Guided Mid-humeral Block	26
BLOCKS AT THE ELBOW	29
Ultrasound Guided Median Nerve Block.....	30
Ultrasound Guided Radial Nerve Block.....	32
Ultrasound Guided Ulnar Nerve Block	34
BLOCKS AT THE WRIST	37
Ultrasound Guided Median Nerve Block.....	38
Ultrasound Guided Ulnar Nerve Block.....	40

LOWER EXTREMITY LANDMARKS	43
LUMBAR NERVE BLOCKS	47
Ultrasound Guided Lumbar Plexus Block	49
Ultrasound Guided Femoral Nerve Block	52
Ultrasound Guided Lateral Femoral Cutaneous Nerve Block	55
Ultrasound Guided Obturator Nerve Block	57
Ultrasound Guided Saphenous Nerve Block	59
SCIATIC NERVE BLOCKS	61
Ultrasound Guided Sciatic Block: Parasacral Approach	65
Ultrasound Guided Sciatic Block: Subgluteal Approach	68
Ultrasound Guided Sciatic Block: Anterior Approach	70
Ultrasound Guided Sciatic Block: Popliteal Approach	72

TABLE OF FIGURES

Figure 1: Anatomical Planes.....	ii
Figure 2: Ultrasound Probes.....	v
Figure 3: Upper Extremity Dermatomes.....	2
Figure 4: Upper Extremity Myotomes.....	3
Figure 5: Upper Extremity Osteotomes.....	4
Figure 6: Martin and Gruber Anastomosis.....	12
Figure 7: Interscalene Block.....	16
Figure 8: Supraclavicular Block.....	18
Figure 9: Supraclavicular Block.....	19
Figure 10: Infraclavicular Block.....	21
Figure 11: Infraclavicular Block.....	22
Figure 12: Axillary Block.....	25
Figure 13: Mid-humeral Block.....	28
Figure 14: Elbow Block - Median Nerve.....	31
Figure 15: Elbow Block - Radial Nerve.....	33
Figure 16: Seated, elbow bent position.....	35
Figure 17: Elbow Block - Ulnar Nerve.....	36
Figure 18: Wrist Block - Median Nerve.....	39

Figure 19: Wrist Block - Ulnar Nerve	41
Figure 20: Lower Extremity Dermatomes	44
Figure 21: Lower Extremity Myotomes	45
Figure 22: Lower Extremity Osteotomes	46
Figure 23: Lumbar Plexus Block.....	51
Figure 24: Femoral Block	54
Figure 25: Lateral Femoral Cutaneous Nerve Block	56
Figure 26: Obturator Nerve Block.....	58
Figure 27: Saphenous Nerve Block.....	60
Figure 28: Sciatic - Parasacral Block.....	67
Figure 29: Sciatic - Subgluteal Block.....	69
Figure 30: Sciatic - Anterior Block	71
Figure 31: Sciatic - Popliteal Block (proximal to the knee).....	74
Figure 32: Sciatic - Popliteal Block (distal to the knee).....	75

INTRODUCTION

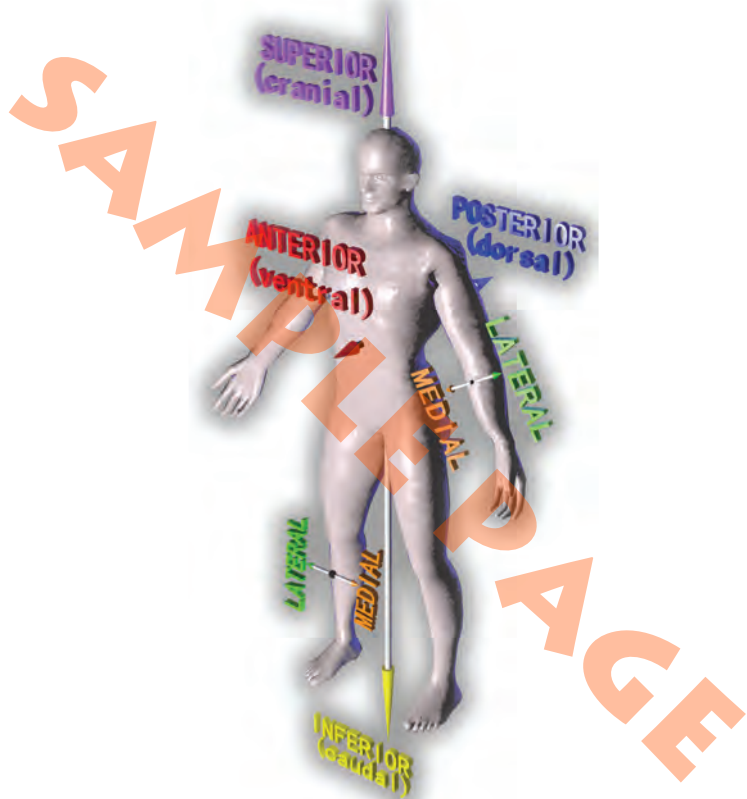


Figure 1: Anatomical Planes

Anatomical Planes & Terminology

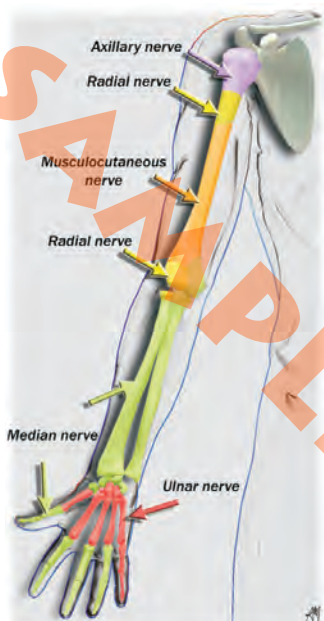
- **Superior (or cranial):** toward the head.
- **Inferior (or caudal):** toward the feet.
- **Anterior (or ventral):** toward the front of the body.
- **Posterior (or dorsal):** toward the back of the body.
- **Medial:** toward the median plane.
- **Lateral:** away from the median plane.
- **Supination:** rotation of the radius around its long axis so that the palm faces anteriorly.
- **Pronation:** rotation of the radius around its long axis so that the palm faces posteriorly.
- **Adduction:** moving toward the median plane.
- **Abduction:** moving away from the median plane.

Ultrasound Terminology

- **Probe / transducer / ultrasound beam:**

A mechanical device that converts one form of energy or signal to another form. In the case of an ultrasound transducer, electrical energy causes a piezoelectric effect on the transducer crystals, creating and transmitting sound waves that are then received back by the transducer and converted into an image on an ultrasound system.

- **Frequency:** Image resolution is proportional to the frequency of the transducer while tissue penetration is inversely proportional to its frequency. Transducers in the highest frequency range (10 - 13 MHz) have the best image resolution but limited depth penetration and are best used for visualization of shallow structures. On the opposite end of the spectrum, a low frequency probe (3 - 5 MHz) will have a greater depth of penetration with better visualization of deeper structures.



ANTERIOR VIEW

POSTERIOR VIEW

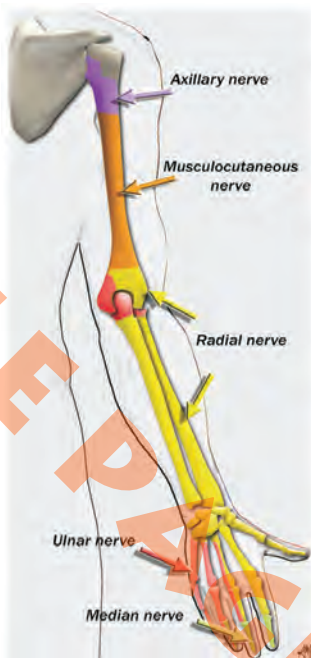


Figure 5: Upper Extremity Osteotomes

BRACHIAL PLEXUS BLOCKS

BRACHIAL PLEXUS

- Formed from anterior primary rami of C5-T1.
- 5 roots, 3 trunks, 3 cords, 5 nerves.
 - ◇ 3 trunks: upper (C5, C6), middle (C7) and lower (C8, T1) in the interscalene space, anterior to scalenus medius and posterior to scalenus anterior.

The trunks pass over the lateral border of the first rib and under the clavicle, each trunk (superior, middle and inferior) divides into anterior and posterior divisions. The divisions reunite to form cords.

- ◇ 3 cords around the axillary artery:
 - » Lateral cord: lateral portion of the median nerve and musculocutaneous nerve.
 - » Medial cord: medial portion of the median nerve, ulnar nerve, medial cutaneous nerve of the forearm and medial cutaneous nerve of the arm.
 - » Posterior cord: axillary and radial nerves.

AXILLARY NERVE

A

- Cervical C5, C6.
- Posterior to the third part of axillary artery.
- Runs laterally to the surgical neck of the humerus.
- Posterior branch comes off the upper lateral nerve of the arm.

S

- Cutaneous innervation of the shoulder.
- Deltoid.
- Shoulder joint.

N

- Contraction of the deltoid.

A

Anatomy

S

Surgical field

N

Neurostimulation

Ultrasound Guided Interscalene Block

Patient Position:

- Supine, head slightly turned to the opposite side.

Landmarks:

- Line (C5-C6) between the thyroid and cricoid cartilages (CC).

Material and Probe Position:

- Linear 6 - 13 MHz probe along the line.

Tips:

- Transverse view of the brachial plexus posterior to a cross sectional view of carotid artery and internal jugular vein.
- Cross sectional view of the trunks between the anterior (AS) and middle scalene (MS) and inferior to the SCM.
- Trunks appear as oval hypoechogenic structures (BP).
- 2-inch needle.
- In-line approach. The needle is inserted at the lateral border of the probe or off-line approach (*preferred by the author*).

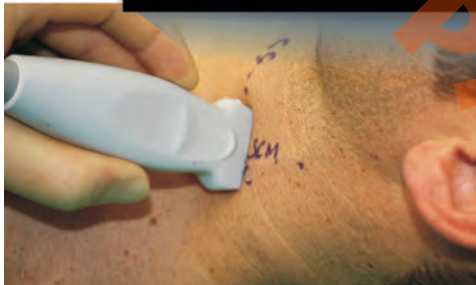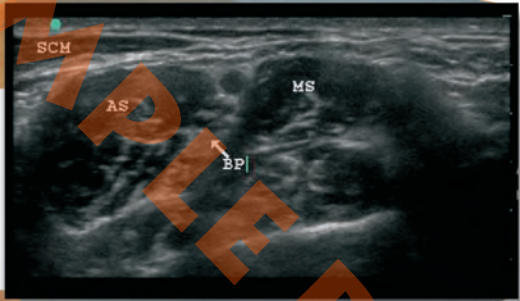
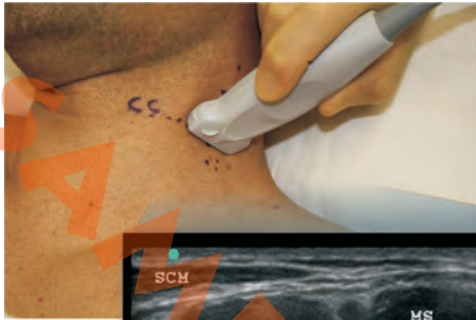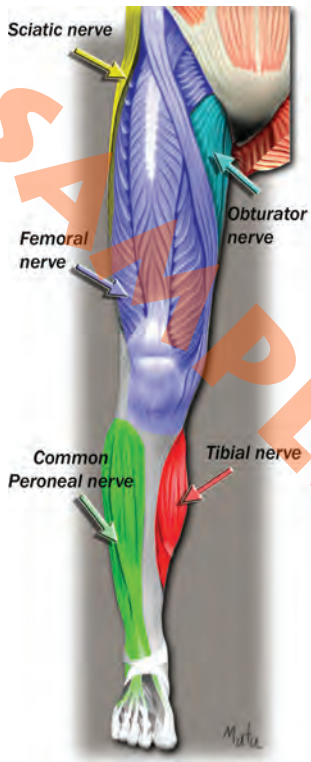


Figure 7: Interscalene Block



ANTERIOR VIEW

POSTERIOR VIEW

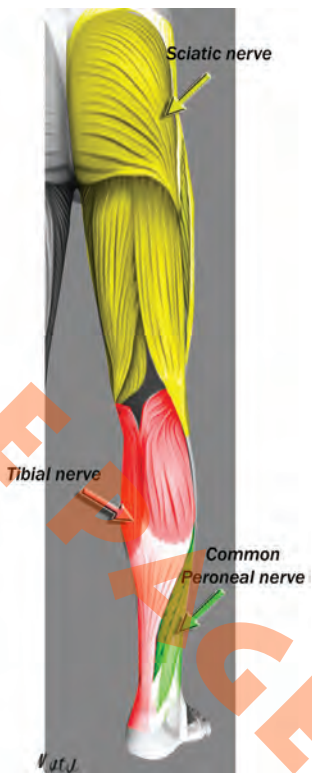


Figure 21: Lower Extremity Myotomes

Ultrasound Guided Sciatic Block: Subgluteal Approach

Patient Position:

- Patient in lateral position, side to be blocked being non dependent with hip and knee flexed (Sim's position).

Landmarks:

- Line between the greater trochanter (GT) and ischial tuberosity (IT).

Material and Probe Position:

- Low frequency 2-5 MHz curved array transducer applied along the line.

Tips:

- Often seen as an almond shaped hyperechoic structure between the lateral IT and medial GT, the S lies deep to the gluteus maximus muscle (GM), superficial to the quadratus femoris muscle, and lateral to the origin of the long head of the biceps femoris.
- In-plane approach (100 mm insulated needle) from the lateral aspect of the probe. A loss of resistance can be perceived when passing through the muscle aponeurosis of the GM.

- The out of plane approach is also possible from the midline of the probe. Hydro-dissection is recommended.
- A simultaneous use of ultrasound guidance and electrical neurostimulation is recommended.

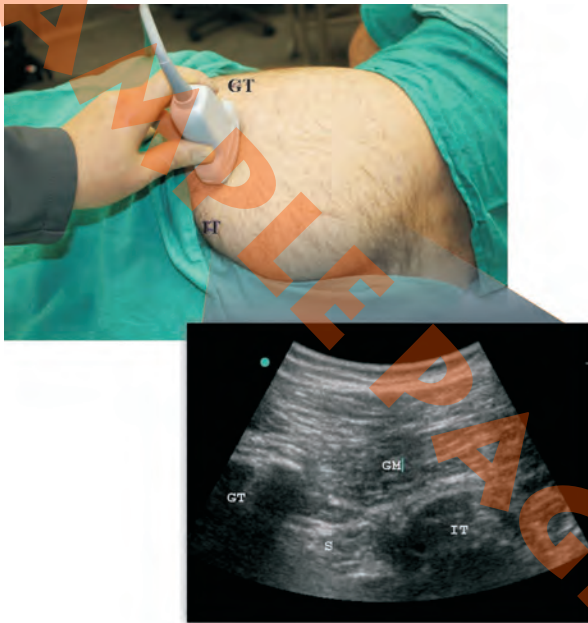

Figure 29: Sciatic - Subgluteal Block

Anesthesiology

Landmarks for ULTRASOUND GUIDED PERIPHERAL NERVE BLOCKS

Upper and Lower Extremities

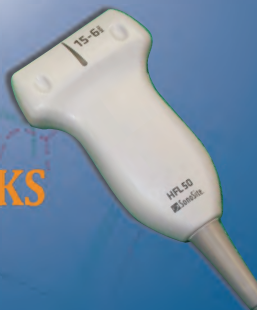2010

Didier A. Sciard, MD

Ultrasonographic visualization of nerves and adjacent structures, with the help of a neuro-stimulator, enhances safe and efficient placement of peripheral nerve blocks.

As a supplement to the *Landmarks for Peripheral Nerve Blocks - Upper and Lower Extremities* pocket book, this new handbook covers the topic of ultrasound guided peripheral nerve blocks, focusing on landmarks with some anatomic considerations and tips.

The learning curve for ultrasound imaging technique and its adaptation to regional anesthesia is steep, but its use provides an invaluable tool and brings the operator considerable satisfaction when performing thoracic, abdominal and peripheral nerve blocks.



Life-Tech[®], Inc.

www.life-tech.com

\$52.00

ISBN 978-0-9752728-2-4



5 5 2 0 0 >

9 780975 272824